

# THREE Y-V FLAP FOR RELEASING OF FIRST WEB SPACE CONTRACTURE OF THE HAND



Kosar Salahaldin Ahmed <sup>a</sup> and Dana Abdulmajid Abdulkarim <sup>b</sup>

Submitted: 19/11/2022; Accepted: 21/4/2023; Published: 21/12/2023

## ABSTRACT

### *Background*

First web space contracture could be caused by burns, infection, trauma, paralytic, arthritis, congenital abnormality, and abnormal immobilization that led to functional limitation of the surgical procedure, including three Y-V flap.

### *Objectives*

To review the outcome of patients with a contracture of the first web space that released contracture using 3Y-V flaps and evaluate the opening degree of the first web space angle.

### *Patients and Methods*

Twenty-eight patients with post-burn contracture of the first web space at Sulaimani Burn and Plastic Surgery Hospital were included from April 2019 to April 2022. The patients were treated using the 3 Y-V plasty technique, and pre-/post-operative angles were measured with a goniometer.

### *Results*

The mean age of the studied patients was  $36.9 \pm 9.0$ . The angle was improved with a preoperative mean value of 39.26 to 58.75 after the operation. Among four recurrent contracture cases, three were due to electrical burns, while another was caused by flap necrosis. Small pieces of skin graft were not the cause of recurrence in this study.

### *Conclusion*

Three Y-V plasty is a successful surgical intervention in reconstructing <sup>the first</sup> web space contracture. However, we suggest excluding patients who cannot use their hands in their daily activities, especially when the contracture is due to electrical burn and associated with nerve injury/muscle contracture; correcting these problems before releasing the contracture is better.

**Keywords:** 3 Y-V plasty, first web space contracture, Burn, Skin graft, angle.

---

<sup>a</sup> Department of Burn and Plastic Surgery, Sulaimani Emergency Hospital, Kurdistan Region, Iraq.

<sup>b</sup> Department of Surgery, College of Medicine, University of Sulaimani, Kurdistan Region, Iraq.

Correspondence: [kosar.salah@yahoo.com](mailto:kosar.salah@yahoo.com)

## INTRODUCTION

First, web space contracture is regarded as a common disability, leading to functional thumb disability with restrictions on its opposition and abduction <sup>(1)</sup>. Functioning the thumb requires adequate length as the thumb becomes shortened when there is a web space contracture <sup>(2)</sup>. The first web contracture caused by hand burn is frequent, although optimal treatment and earlier physiotherapy/surgical interventions were applied <sup>(3)</sup>. Severe burns cause scars and contractures, specifically in joints, leading to disability <sup>(4)</sup>. Damaging hand skin and soft tissue lead to adduction contractures either caused by web space burn contracture or abnormal long adduction position in addition to short adductor pollicis <sup>(5)</sup>. During contracture release, it is important to release or excise fibrous tissue to increase abduction and adduction of the thumb and decrease the chance of recurrence <sup>(6)</sup>. The surgeon has to release all previously functional and healthy structures to move the thumb easily and make a good first web space angle <sup>(7)</sup>.

The first web space contracture complicates hand burns even when the primary burn healing is successfully documented. It was shown that first web contractures are highly incidental in hand burns with delayed healing <sup>(8)</sup>. Burn-caused first web space contracture could be categorized into four grades; grade I, which involves normal configuration with tightness and no movement limiting, is reported, while grade II is characterized by mild limitation of movement but without effect on daily living or abnormal configuration. Grade III is manifested by obvious dysfunction and earlier configuration of the hand, while grade IV causes a complete loss of function and seriously distorted hand architecture <sup>(9)</sup>. The surgical management of first web space contractures involves paganization and relative thumb lengthening, specifically for distal injuries to the middle third of the proximal phalanx of the thumb. Due to accompanying adduction, this procedure requires a wide deepening first web space. For successful web deepening, relative malleability of local skin, mobility of thumb metacarpals, contracted intrinsic muscles, and intact thumb length (half at least) are required <sup>(10)</sup>.

Many local and regional surgical flaps are used to manage first web space, including Z-plasty, Y-V plasty with multiple variants, spinner flap, four-flaps, five-flap techniques, and reverse posterior interosseous flap <sup>(11)</sup>. All these reconstructive procedures aim to release contractures and restore movement <sup>(5)</sup>. In Y-V plasty, there is an ability to provide a tailored flap to release

web space defects. Additionally, better and earlier postoperative hand mobility is reported following Y-V plasty. The common advantage of Y-V plasty is the ability to repeat the procedure if contracture reoccurs. It is routinely implemented in Dupuytren's contractures with high precision and low complications in addition to importing local skin <sup>(12)</sup>. Better lengthening of the original scar and planning the Y-V plasty is simple, flexible and adjustable <sup>(13)</sup>.

Hand burn accidents in Iraq are common and need special care <sup>(14)</sup>. Multiple surgical flaps are nationally used to manage burn contractures <sup>(15)</sup> successfully. However, the national surgeons are focusing on Z-plasty with the scarcity of national literature discussing the outcome of Y-V plasty in correcting first web space contractures following burns. Thus, this study aimed to evaluate the degree of post-burn contracture release of the <sup>first</sup> web space and the degree of opening of the angle of the <sup>first</sup> web space after releasing the contracture using 3Y-V plasty.

## PATIENTS AND METHODS

A total of 28 patients with post-burn contracture of the first web space at Sulaimani Burn and Plastic Surgery Hospital, Iraq, were included from April 2019 to April 2022.

### *Inclusion criteria*

Patients with post-burn contracture scars in the first web space that affect their daily activities due to not moving their thumb were comfortably included in this study regardless of age and gender.

### *Exclusion criteria*

Patients with the absence of the supple joint of the contracted finger (arthrodesis of carpometacarpal/metacarpophalangeal joints) were excluded from the study.

### *Ethical consideration*

Approval was taken from the Kurdistan Board for Medical Specialties ethics committee. Informed consent was taken verbally by the researcher from each patient enrolled in the study. Confidentiality was taken into consideration.

### *Surgical technique*

All surgeries were done under general anaesthesia. After the patient was prepared, the linear scar was

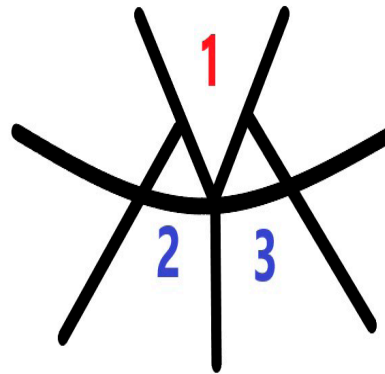
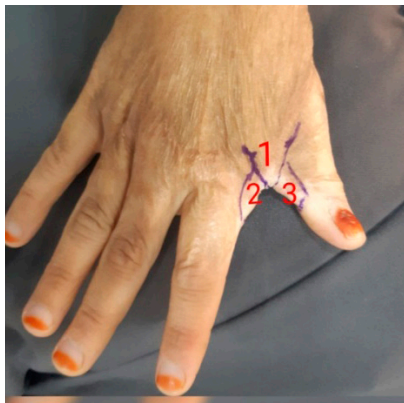
### Three Y-V Flap for Releasing of First Web Space Contracture of the Hand

marked in the contracted first web space. The first central flap was marked on that side which was not burned previously, but if both the palmar and dorsum of the first web space were burned, we chose the dorsum for the central flap to make a dorsal inclination of the first web space and two other flaps marked on another surface. The tip of the first central flap (flap 1) was on the linear scar contracture, and the two other flaps (flap two and flap 3) crossed the linear contracture scar (middle of the flap located on the contracture line) (Figure 1). The shape of the flaps was V, and from the tip of the flap, a line changing the V to Y shape was drawn. The length of web creep determined the length of these lines, and these markings were done when the finger was abducted passively. A tourniquet was used for most cases; the incision was made with the number 15 blade undermining the flap (epidermis, dermis, and subcutaneous tissues elevated) (Figure 2B), and fibrosis/scars under the flap were released. Then, the incision was made from the tip of the V flap to the area

that needed to be depressed (web creep did not remain), and the tip of the V flap advanced to the end of the incision. A 6.0 prolene suture with a skin graft was used in 50% of cases, while in 35.7% of cases, only one small piece of skin graft <1 cm (Figure 2C) and in 14.4%, two small pieces of skin graft <1cm were used with a tight dressing. The patients were followed up for six months.

#### Statistical analysis

All patients' data were analyzed using Statistical Package for Social Science (SPSS, Chicago, USA version 25.0). Descriptive statistics were presented as mean± standard deviation and frequencies as percentages, the Chi-square test was used for categorical variables, and an independent T-test was used to compare between means. A P-value of <0.05 was considered statistically significant.



**Figure 1.** Shows the tip of the first central flap (flap 1) on the linear scar contracture and the two other flaps (flap two and flap 3) that crossed the linear contracture scar.

## RESULTS

The mean age of study patients (n=28) was 36.11±9.18 years. About 89.3% were females (n=25), and 10.7% were males (n=3). The contractures in 3 cases were caused by electrical burn and in another 25 cases caused by flame burn (Table 1 and Figure 2A).

The angle of the first web space preoperatively and 1 week/6 month postoperatively were measured. The mean preoperative angle was 39.26±4.95, while it was 54.21±5.25 and 58.75±7.29 after one week and six months from the operation, respectively (Table 2).

In 85.72% (24 cases), the degree of angle was increased by approximately 19 degrees, and these patients were

satisfied with it in their daily activities (Figure 2D). The recurrence was found in 14.28% (4 cases), and the degree of angle was not increased in 6 months follow-up. In 3 out of these 4 cases, the contractures were caused by the electrical burn that had other comorbidities such as nerve injury or muscle contracture that impaired them from doing physiotherapy postoperatively. Another patient with flame burns developed necrosis of a central flap, and the degree of angle of the web space was not increased after six months. Consequently, the same procedure was repeated for her after three months. However, the process was not repeated for the other three patients as they could not do physiotherapy or even use their hands in their daily activities.

In this research, a small piece of skin graft does not increase the risk of recurrence. However, if a large piece of skin graft is needed, it can be divided into two pieces and should be grafted in 2 areas with placement on the peripheries of the released area and not beside the central flap.

The mean preoperative angle was  $41.36 \pm 4.0$  when we used one piece of small skin graft after releasing the contracture with 3Y-V flaps. The postoperative angle after six months turned to  $59.79 \pm 6.96$ . Moreover, when we used two pieces of small skin graft, the mean preoperative angle was  $32.25 \pm 1.0$  and six months postoperatively, it became  $56.3 \pm 5.28$ . However, the mean preoperative angle was  $39.76 \pm 4.55$  (without skin graft) (Table 3).

Only in one case did a distal of central flap necrosis occur with a non-significant difference. However, her contracture recurred clinically, and her preoperative angle was 47.2, which increased to 57.80 one week after the operation. He had necrosis at the tip of the central flap; the dressing was done to her, and she was followed up. Six months after the operation, the angle became 48.0, and the contracture recurred (Table 4). Consequently, the same procedure was done to her three months after the recurrence. The necrosis did not occur, and the degree of angle was increased very well, which led to her satisfaction.

**Table1. Sociodemographic characteristics and causes of contracture in studied patients.**

Variable	Mean±SD	Frequency	Percentage
<b>Age (Year)</b>			36.11±9.18
<b>Gender</b>	Female	25	89.3
	Male	3.0	10.7
<b>Occupation</b>	Housewife	22	78.6
	Student	3.0	10.3
	Worker	3.0	10.3
<b>Cause</b>	Electrical burn	3.0	10.7
	Flame burn	25	89.3
<b>Total</b>		28	100

**Table 2. The degree of angle preoperatively and 1 week/ 6 month postoperatively.**

Follow up	Variable	Mean±SD	P-value
<b>Pair 1</b>	Preoperative angle	39.26±4.95	0.005
	Postoperative angle after one week	54.21±5.25	
<b>Pair 2</b>	Preoperative angle	39.26±4.95	0.867
	Postoperative angle after six months	58.75±7.29	
<b>Pair 3</b>	Postoperative angle after one-week	54.21±5.25	<0.001
	Postoperative angle after six months	58.75±7.29	

Three Y-V Flap for Releasing of First Web Space Contracture of the Hand

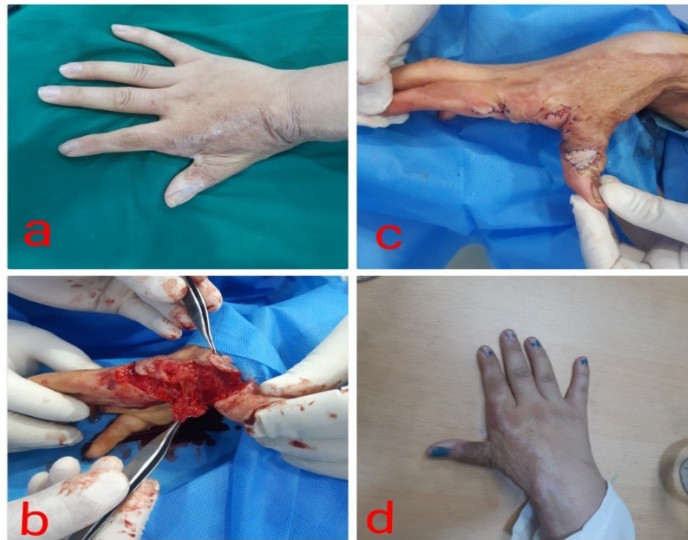

Figure 2. Shows preoperative patient's hand (a), intraoperative flap elevation (b), directly postoperative using one small piece of skin graft (c), and postoperative after six months (d).

Table 3. The effect of the skin graft on the first web space angle after using 3 Y-V flaps.

Skin graft	Preoperative Mean±SD	Postoperative after one week Mean±SD	Postoperative after six months Mean±SD
1 piece < 1cm	41.36±4.02	55.75±3.31	59.79±6.96
2 pieces < 1cm	32.25±1.04	50.55±1.66	56.30±5.28
Not using	39.76±4.55	54.15±6.56	55.70±8.22
<b>Total</b>	39.26±4.95	54.21±5.25	58.75±7.29
<b>P- value</b>	0.003	0.254	0.735

Table 4. Shows the effect of flap necrosis on contracture recurrence.

Flap necrosis	Preoperatively Mean±SD	Postoperatively, after one week Mean±SD	Postoperatively, after six months Mean±SD
No	38.96±4.79	54.97±5.3	59.14±7.11
Yes	47.2±0.0	57.8±0.0	48.0±0.0
<b>Total</b>	39.26±4.95	54.21±5.25	58.75±7.29
<b>P-value</b>	0.10	0.49	0.13

## DISCUSSION

Hand burn complications, especially first web space contractures, disrupt quality of life and lead to physical and psychological abnormalities. Surgical intervention by releasing contractures is an important step in management <sup>(16)</sup>.

Regarding the sociodemographic data, in the present study, the mean age of patients with first web space contracture was 36.11±9.18 years, which is close to the results of Ibraheem et al. 2008 prospective study in Iraq on ten patients with hand deformities who found that the mean age of the patients to be 38 years <sup>(17)</sup>. Our study revealed that female patients were predominant with first web space contracture, which coincides with the results of the Mehta et al. 2019 prospective study in India, which reported a high predominance of females with hand burn contractures <sup>(18)</sup>. Afzal et al. 2019 in Pakistan reported a predominance of males in post-burn first web space contracture <sup>(19)</sup>. This inconsistency might be attributed to differences in burn causes, occupational hazards and burn epidemiology between different countries.

In our study, the flame burn was the commonest cause of first web space contracture, which agreed with Fufa et al. 2014 review study in the USA, which stated that flame burn was the common cause of hand burns and first web space contracture <sup>(20)</sup>. The high prevalence of flame burn is because most cases in the present study were housewife females affected by home-based burns, not occupational burns.

In this study, we used a 3Y-V flap; the tip of the central V flap was located on the contracture line, while the central two other flaps were located on the contracture line. These were our variations in the flap design when compared to the previous multiple Y-V flaps, which was the contracture line located on the centre of all flaps, and more than three flaps were used <sup>(21, 22)</sup>. In the current study, the degree of angle of first web space was significantly increased six months post-Y-V plasty in most patients ( $p < 0.001$ ). This finding was similar to Ahmed's 2016 study <sup>(17)</sup> in Egypt, who reported that after five flap z-plasty, skin graft and groin pedicle flap for patients with first web space contracture, most of the patients achieved a full range of movement, but not for patients with affected joints <sup>(23)</sup>.

Moreover, the recurrence was reported in 4 cases (14.28%) with first web space contracture, which was close to the results of the Murat 2010 study in Turkey,

which reported the recurrence in 10% of cases <sup>(24)</sup>. The cause of recurrence in our study after Y-V plasty was mainly due to electrical burn in 3 cases with ulnar nerve injury, so they could not use their hand in their daily activities and could not do postoperative physiotherapy. In this respect, Harvey et al. 2017 clarified that it is important to do physiotherapy to treat and prevent contracture <sup>(25)</sup>. This may be the cause of recurrence in our patient. Thus, the operation was not repeated for them. The other recurrence was caused by flame burn, but flap necrosis occurred after releasing by 3 Y-V plasty, and recurrence after a 6-month follow-up was observed. Therefore, the same procedure was done for this patient, which was successful without flap necrosis and re-recurrence. This finding coincides with the results of Bai et al. 2019 prospective study in India, which documented that electrical burns caused severe contracture with a high recurrence rate after release <sup>(26)</sup>. In Egypt, a clinical trial study was conducted by Mohamed et al. 2022 on four groups of patients ( $n=29$ ) with first web space contracture treated by different methods. It revealed that the success of a release was related to the amount of opposition obtained. It was challenging to achieve equivalent opposition to the unaffected hand <sup>(27)</sup>.

Furthermore, we realized that using a skin graft did not increase the risk of recurrence as we used a small piece and placed the pieces onto areas not used in one area. This finding was consistent with reports by Lim et al. 2020 study in Singapore, who documented that using more than one small skin graft piece would not affect the postoperative recurrence or angulations <sup>(28)</sup>. Also, Hur et al. (2014) illustrated that the percentage of contracture after skin grafting increased more if the size of the skin graft was larger <sup>(29)</sup>.

The flap necrosis in our study was only encountered in one studied patient managed by 3 Y-V plasty. Although this case was statistically insignificant, clinically, it was one of the causes of contracture recurrence in our study. In this regard, Mahmoud et al. 2013) observed flap necrosis and tip flap loss, increasing the chance of contracture recurrence <sup>(30)</sup>.

Generally, when compared to Z-plasty, the 3 Y-V plasty is considered a safe, effective and less morbid technique in managing first web space contracture <sup>(22, 24)</sup>.

In conclusion, the 3 Y-V plasty is a successful surgical intervention in reconstructing the first web space contracture. The 3 V-Y plasty outcome is not

## Three Y-V Flap for Releasing of First Web Space Contracture of the Hand

affected by several used skin grafts, but flap necrosis leads to recurrence while statistically insignificant. In addition, severe contractures caused by electrical burns are accompanied by poor 3 Y-V plasty outcomes, thus encouraging surgeons to adopt the 3 Y-V plasty in managing the first web space contracture. Our outcomes further support national multi-centre studies that evaluated the different surgical methods in treating first web space contracture.

### REFERENCES

1. Therattil PJ, Datiashvili RO. First web space contracture. *Eplasty*. 2014;14: ic28.
2. Graham DJ, Venkatramani H, Sabapathy SR. Current reconstruction options for traumatic thumb loss. *The Journal of Hand Surgery*. 2016; 41(12):1159-1169.
3. Kola N, Isaraj S, Belba G. Planning and technical details when treating a post-burn hand contracture. *Annals of Burns and Fire Disasters*. 2006; 19(4):208-211.
4. Aslan G, Sarifakioglu N, Tuncali D, Terzioglu A, Bingul F. The prepuce and circumcision: Dual application as a graft. *Annals of Plastic Surgery*. 2004; 52(2):199-203.
5. Bhattacharya S. Avoiding unfavorable results in postburn contracture hand. *Indian journal of plastic surgery*. 2013; 46(2):434.
6. Sabapathy SR, Bajantri B, Bharathi RR. Management of post-burn hand deformities. *Indian Journal of Plastic Surgery*. 2010; 43(Suppl):S72.
7. Kumar S, Khan FAA, Ali H, Kiran S. Surgical Management of Post Burn Hand Deformities. *Pakistan Journal of Medical Sciences*. 2020; 36(6):1387.
8. Sunil NP, Ahmed F, Jash PK, Gupta M, Suba S. Study on surgical management of post-burn hand deformities. *Journal of Clinical and Diagnostic Research*. 2015; 9(8):PC06.
9. McCauley RL. Reconstruction of the pediatric burned hand. *Hand Clinics*. 2009; 25(4):543-550.
10. Pet MA, Ko JH, Vedder NB. Reconstruction of the traumatized thumb. *Plastic and Reconstructive Surgery*. 2014; 134(6):1235-1245.
11. Kai S, Zhao J, Jin Z, Wu W, Yang M, Wang Y, et al. Release of severe post-burn contracture of the first web space using the reverse posterior interosseous flap: our experience with 12 cases. *Burns*. 2013; 39(6):1285-1289.
12. Kartal SP, Altunel CT, Bayramgurler D. Introductory Chapter: An Introduction in Burn Injury. In: *Hot Topics in burn injuries: BoD–Books on Demand*. Kartal SP and Bayramgurler D. 1st ed. United Kingdom: IntechOpen; 2018. P. 3-17.
13. van Niekerk WJ, Taggart I. The size of the Y: the multiple YV plasty revisited. *Burns*. 2008; 34(2):257-261.
14. Altai HS. Special Care for Hand Burns. *Medical Journal of Babylon*. 2014; 11(1):144-151.
15. Hasan RA, Attai HS. Evaluation of Release of Wide Post Burn Contracture of Joints Using Central Axis Propeller Flap. *Iraqi Postgraduate Medical Journal*. 2021;20(2):178-185.
16. Güven E, Uğurlu AM, Hocaoglu E, Kuvat SV, Elbey H. Treatment of post-burn upper extremity, neck and facial contractures: report of 77 cases. *Turkish Journal of Trauma & Emergency Surgery*. 2010; 16(5):401-406.
17. Ibraheem OA, Abood MH, Tayah H. Evaluation of the posterior interosseous artery flap in reconstructing hand defects. *Iraqi Postgrad Medical Journal*. 2008; 7(2):157-163.
18. Mehta MA, Ranjan V, Kulkarni AK, Sarwade P. Clinicoepidemiological study of post-burn contractures at a tertiary care centre in western India. *International Surgery Journal*. 2019; 6(6):1896-900.
19. Afzal MO, Tarar MN, Rafi Y. Reconstruction of the Post Burn First Web Space Contractures of Hand with Square Flap: Efficacy of the technique. *Pakistan Journal of Medical Sciences*. 2019; 13(1):176-180.
20. Fufa DT, Chuang S-S, Yang J-Y. Prevention and surgical management of postburn contractures of the hand. *Current Reviews in Musculoskeletal Medicine*. 2014; 7(1):53-59.
21. Shehab El Din SA, Younis RA, Khater AM. Correction of Cord Like Scars Using Running Opposing YV Plasty. *The Egyptian Journal of Plastic and Reconstructive Surgery*. 2018; 42(2):411-414.
22. Nikkhah D, Reissis D, Shibu M. The Y-V is plasty for the first web space release. *Journal of Hand Surgery*. 2018; 43(3):337-338.
23. Ahmed A. Reconstruction of postburn contracture of first web space of the hand. *Zagazig University Medical Journal*. 2016; 22(3):1-9.
24. Murat Emsen I. A new method in the treatment of postburn and post-traumatic scar contractures: Double-opposing Z-and V-(KMN) plasty. *Canadian Journal of Plastic Surgery*. 2010; 18(2):20-26.
25. Harvey LA, Katalinic OM, Herbert RD, Moseley AM, Lannin NA, Schurr K. Stretch for the treatment and prevention of contracture: an abridged republication of a Cochrane Systematic Review. *Journal of Physiotherapy*. 2017; 63(2):67-75.

26. Bai SPL, Gunasekaran R. Post-burn flexion contracture of hand: a prospective study. *International Surgery Journal*. 2019; 6(8):2823-2827.
27. Mohamed MA, Keshk TF, Taalab AA, Selim AM. Different options for the first web-space reconstruction. *Menoufia Medical Journal*. 2022; 35(1):307-312.
28. Lim JX, Chung KC. VY advancement, thenar flap, and cross-finger flaps. *Hand Clinics*. 2020; 36(1):19-32.
29. Hur G-Y, Seo D-K, Lee J-W. Contracture of skin graft in human burns: effect of artificial dermis. *Burns*. 2014; 40(8):1497-1503.
30. Mahmoud M, Abdel-Ghani H, Elfar JC. A new flap is needed for widening the web space and correcting palmar contracture in the complex clasped thumb. *The Journal of Hand Surgery*. 2013; 38(11):2251-2256.